

## ARANEISM IN ADULT MALE CAUSED BY *Zorocrates* sp: A CASE IN MORELOS STATE, MEXICO

Héctor Gabriel Ramos Rodríguez<sup>1</sup>, César Raziel Lucio Palacio<sup>2</sup> and José D. Méndez<sup>3\*</sup>

<sup>1</sup>Gerontology Module. Tlalpan Family Medicine Clinic. Instituto de Seguridad y Servicios Sociales de los Trabajadores del Estado. Mexico City, Mexico.

<sup>2</sup>Grupo Académico Interacción, Adaptación y Biodiversidad, GAIA-BIO. Departamento de Conservación de la Biodiversidad. El Colegio de la Frontera Sur (ECOSUR), Unidad Chetumal.

<sup>3</sup>Medical Research Unit in Metabolic Diseases. Cardiology Hospital. Instituto Mexicano del Seguro Social. Mexico City, Mexico.

Article Received on  
21 Oct. 2019,

Revised on 11 Nov. 2019,  
Accepted on 01 Dec. 2019,

DOI: 10.20959/wjpr20201-16401

### \*Corresponding Author

**Dr. José D. Méndez**

Medical Research Unit in  
Metabolic Diseases.  
Cardiology Hospital.  
Instituto Mexicano del  
Seguro Social. Mexico City,  
Mexico.

### ABSTRACT

In the Americas, the largest number of cases of araneism is due to the genera *Loxosceles*, *Latrodectus* and *Phoneutria*. However, in Mexico there are no specific records of cases of araneidic accident, which makes it impossible to determine their epidemiology. Cases provoked by *Kukulcania tractans* and *Zorocrates guerrerensis* with favorable clinical evolution and lesions of variable intensity are known. The case of the bite of *Zorocrates* sp. in a 44-year-old male is presented. The clinical picture, without systemic involvement, lasted 75 days without complications or sequelae after receiving conservative medical treatment.

**KEYWORDS:** Araneism, *Zorocrates*, spider venom, venom, envenomation, animal toxins.

### INTRODUCTION

The poisoning by species of scorpions, spiders, caterpillars and snakes, in the different latitudes of the American Continent, is considered a little explored field in the different levels of medical attention, both urban and rural, which constitutes one of the greatest challenges in the assistance of accidents with poisonous animals, given that the response, diagnosis and treatment time is a fundamental factor in complications and sequelae and, in severe cases, in

the threat of death of the affected persons.<sup>[1]</sup> The main cases of araneism that are known in the Americas involve species of *Latrodectus* (Theridiidae), *Loxosceles* (Sicariidae) or *Phoneutria* (Ctenidae) genus.

Spiders occupy an interesting position in human society and in medicine. The overall health risk that they pose is minor compared with other routine events such as driving an automobile, vocational and recreational hazards, or living an unhealthy lifestyle. In North America, spider envenomation is perceived to be a greater threat than in actuality; however, it is still a valid source of morbidity and, very rarely, mortality. Only two groups (widows, recluses) are medically important on this region.<sup>[2]</sup>

Spiders, like scorpions, stand out for their importance in public health because their bite is occasionally harmful to humans. They all use the poison to kill their prey and as a defense mechanism, but if we consider their dimensions, the amount of the inoculum and the fragility of their inoculator organs rarely cause serious injuries to people.<sup>[3]</sup> Of the 48, 342 species included in the World Spider Catalog (WSC, Version 20.5), only some species (2.0%) are considered of medical importance in the International Classification of Diseases (ICD-11): Brown recluse spider, False widow spider, Funnel web spider, Hobo spider, Jumping spider, Mouse spider, Six eyed sand spider, Tarantula spider, Wandering spider, Widow spider, Wolf spider, and Yellow sac spider (Table 1). *Hexophthalma* of the family Sicariidae<sup>[4-6]</sup> should be included in the six-eyed spiders.

The first case of necrotic araneism by *Zorocrates guerrerensis* Gertsch & Davis, 1940 from Mexico (in the Mexico City, Iztapalapa Delegation) is known, with medical treatment included the antivenom ARACMYNPLUS<sup>®</sup>, tetanus toxoid, and prophylactic antibiotic against anaerobic germs, with satisfactory evolution.<sup>[7]</sup> In Mexico, although there is a underreporting of spider bites, most cases are due to *Latrodectus* and *Loxosceles*, a situation that prevents us from knowing the general epidemiology of araneism in our country. In addition, the arachno-fauna of our country has been partially studied over the years, which determines the poor knowledge of taxa of clinical importance, coupled with the absence of texts and manuals that facilitate the identification of these arthropods.<sup>[8]</sup> In the State of Morelos, the presence of *Zorocrates fuscus* and *Zorocrates bosencheve*<sup>[9]</sup> are known. In the present case, the specific identification of the specimen was not made due to its loss. Multidisciplinary interaction is essential for the efficient approach to spider poisoning, both in humans and animals.

**Table 1: Coding of spiders in the International Classification of Diseases.**<sup>[5]</sup>

<p><b>XM6NN5 Spider venom</b>  XM2RM6 Brown recluse spider venom  Violin spider venom  XM6SD4 False widow spider venom  Rabbit hutch spider venom  XM3KD6 Funnel web spider venom  XM57S7 Hobo spider venom  XM0C68 Jumping spider venom  Zebra spider venom  XM1LF5 Mouse spider venom  XM6QH2 Six eyed sand spider venom  Six eyed crab spider venom  XM8095 Tarantula spider venom  XM8FT7 Wandering spider venom  Banana spider venom  Brazilian wandering spider venom  XM7JS2 Widow spider venom  XM7M21 Black widow spider venom  XM9Z42 Brown widow spider venom  XM1TF6 Redback spider venom  XM2JA0 Red widow spider venom  XM2WM2 Wolf spider venom  XM3UW9 Yellow sac spider venom</p>
--------------------------------------------------------------------------------------------------------------------------------------------------------------------------------------------------------------------------------------------------------------------------------------------------------------------------------------------------------------------------------------------------------------------------------------------------------------------------------------------------------------------------------------------------------------------------------------------------------------------------------------------------------------------------------------------------------------------------------------------------------------------------------------------

**Clinical Case**

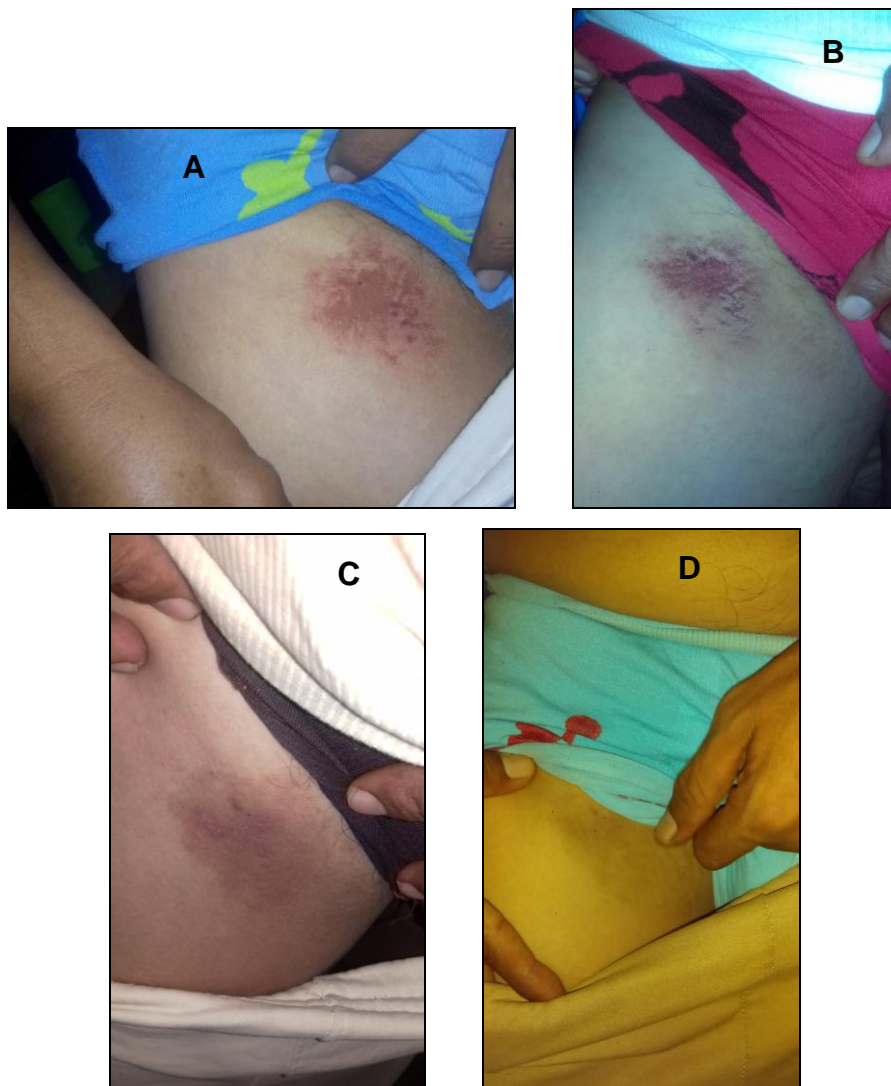
A 44-year-old male, originally from Puente de Ixtla and currently residing in Atlacholoaya, Municipality of Xochitepec in Morelos, México (Maps 1 and 2). Merchant, single, good personal hygiene, regular food, urban services of low quality, overcrowding and consumption of marijuana. Mentions being heterosexual, denies allergic and concomitant conditions.

At night, during sleep, it starts with itching of mild to moderate intensity in the right inguinal region, so when clothes are removed, dark spider arachnid of approximately 2 cm in length fell, it was caught and kept in a plastic bottle with alcohol for conservation. The physical examination is oriented in time, person and place with blood pressure 120/80, heart rate 72 bpm, temperature of 36.4 ° C, weight 80 kg. and size 1.73 m.

Presence of maculopapular lesion and livedoid type plate with irregular contours, approximately 8-9 cm in diameter with scratch marks (Figure 1).<sup>[10]</sup> After 24 hours, presence of satellite maculopapular lesions (which remain until day 18), with mild pain on superficial palpation and mild to moderate itching that is exacerbated when bathing with hot water. The itching continued for a week. Without systematization, with relief when cold water is applied

to the lesion, preserved right lower limb mobility and, femoral and popliteal arterial pulses without alterations.

Received treatment with Loratadine 10 mg. one c / 8 hours *v.o.*, Cephalexin 500 mg one c / 8 hours for 8 days *v.o.*, daily washing of the affected region with soap and water; also, application of tetanus toxoid. The toxoid was not administered. On the second day after the bite Paracetamol 500 mg was added, one c / 8 hours. After 75 days of the araneidic accident, presence of non-painful hyperchromic spot and without maculopapular lesions.



**Figure 1: Clinical evolution: A) Livedoid type plate with maculopapular lesion, eight hours after the bite. B) Livedoid type plate in involution with satellite maculopapular lesions, after 24 hours. C) Decrease in plaque coloration and maculopapular lesions numerous at 18 days and D) Livedoid type plate in resolution without maculopapular lesions after 75 days (Photos: Christian Ramos O.).**

## THE SPIDER

The genus *Zorocrates* (Figure 2) belongs to the family Zoropsidae and is composed of medium-sized spiders (0.5 to 1.7 cm in body length), with eight eyes arranged in two parallel lines. The middle anterior eyes are smaller than the rest. The members of this genus have an oval carapace, a long, straight and relatively deep thoracic groove and the body covered with short and reclining setae, with a few that are long and erect and are concentrated in the ocular region. In addition, they have three pro-marginal teeth in the chelicera and tarsus have usually three claws. Additionally, most of the members of this genus have a cribellum and calamistrum.<sup>[9]</sup>

The absence of distinctive color patterns and the homogeneity of appearance and size among the members of the genus make identification at the species level possible only when examining genital organs of adult specimens. Little is known about the biology and natural history of *Zorocrates* spiders. The life cycle of *Zorocrates guerrerensis* is annual.<sup>[11]</sup> Spiders of this genus are part of the diet of snakes of the genus *Conopsis*.<sup>[12]</sup>

There are 31 species of *Zorocrates* (Table 2), of which five are shared between the US and Mexico, two are found from Mexico to countries in Central America and the remaining 24 are exclusively Mexican species (Platnick & Ubick 2007).<sup>[11]</sup> The ones with the greatest distribution are: *Zorocrates unicolor*, *Zorocrates fuscus*, *Zorocrates guerrerensis* and *Zorocrates gnaphosoides*. The first is reported in the US (Arizona and Texas), and in fifteen Mexican states: Aguascalientes, Chihuahua, Durango, Guanajuato, Guerrero, Hidalgo, Jalisco, Mexico, Michoacán, Nuevo León, Oaxaca, San Luis Potosí, Sonora, Tabasco, and Tamaulipas. *Zorocrates fuscus*, in Mexico City, Guanajuato, Guerrero, Hidalgo, Jalisco, Mexico, Michoacán, Morelos, Oaxaca, Puebla, San Luis Potosí, Tlaxcala, Veracruz, and Zacatecas. It is known as a synanthropic species in Mexico City<sup>[14]</sup> and Toluca.<sup>[13]</sup> *Zorocrates guerrerensis*, is found in Chiapas, Guerrero, Oaxaca, Puebla, Panama and *Zorocrates gnaphosoides*, is reported in Chiapas, Puebla, Veracruz, Guatemala, and El Salvador.<sup>[13, 14]</sup>

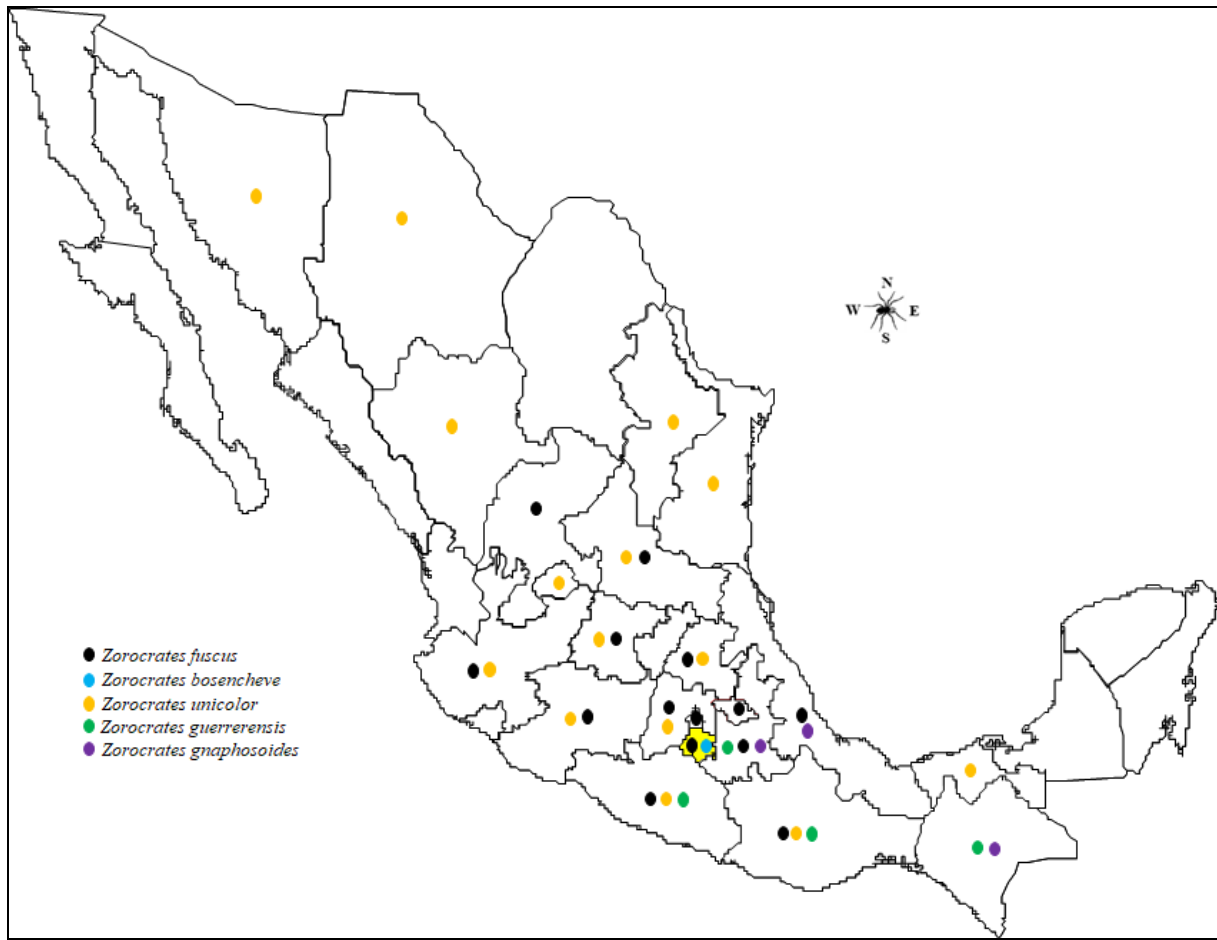


**Figure 2:** *Zorocrates* sp. (from the Greek *zóros* = dark and *krátos* = corpulent)<sup>[15]</sup>; House spider or fake wolf spider. A) Dorsal view and B) Ventral view (Photos: Ana Luz Salgado R.).

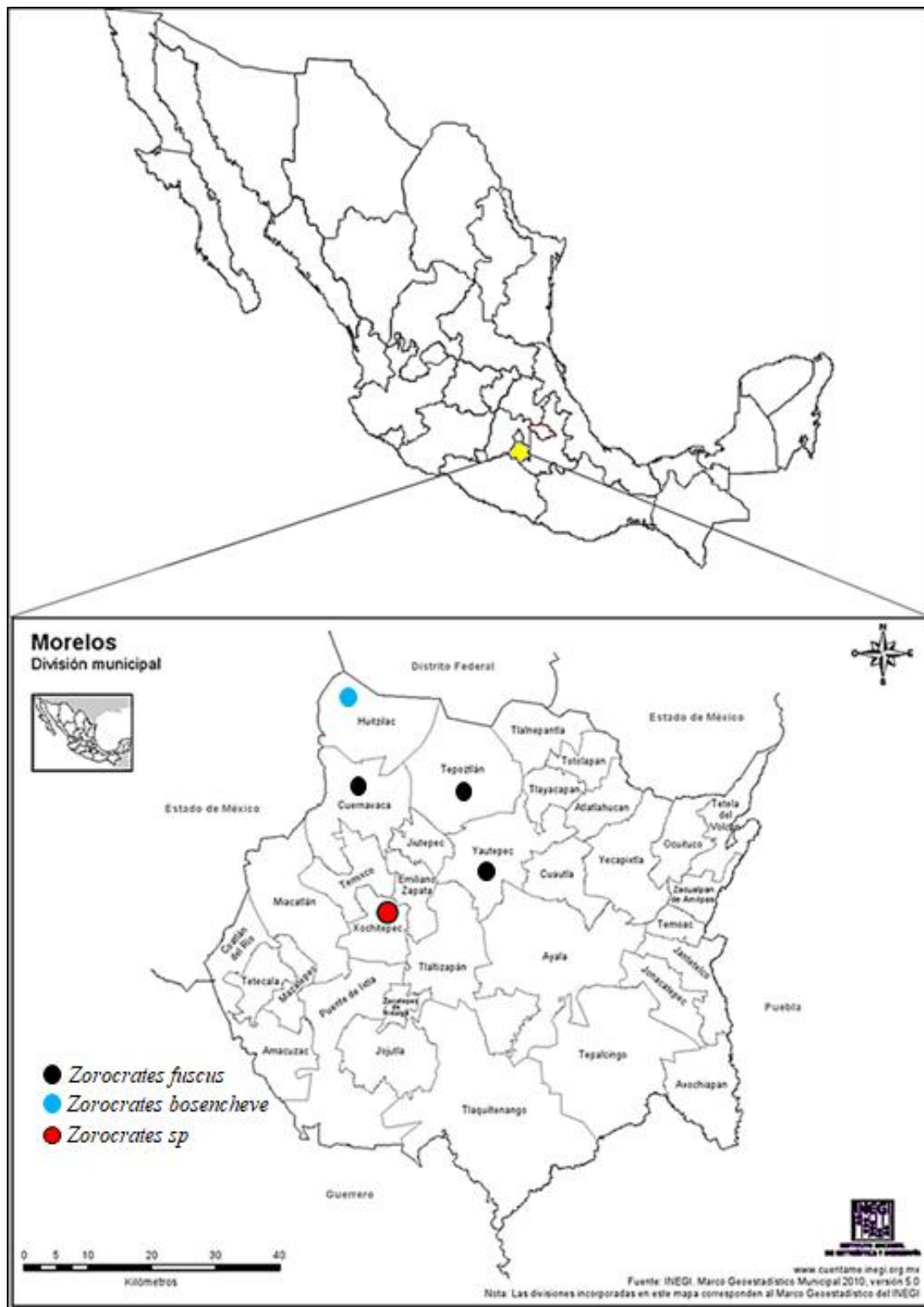
**Table 2:** Geographical distribution of the genus *Zorocrates* (Simon, 1888) according with WSC, Version 20.5.<sup>[16]</sup>

SPECIES	LOCATION
<i>apulco</i> <sup>3</sup> , <i>badius</i> <sup>4</sup> , <i>blas</i> <sup>3</sup> , <i>bosencheve</i> <sup>3</sup> , <i>chamela</i> <sup>3</sup> , <i>chamula</i> <sup>3</sup> , <i>chiapa</i> <sup>3</sup> , <i>colima</i> <sup>3</sup> , <i>contreras</i> <sup>3</sup> , <i>fuscus</i> <sup>5</sup> , <i>huatusco</i> <sup>3</sup> , <i>mistus</i> <sup>9</sup> , <i>mordax</i> <sup>10</sup> , <i>nochix</i> <sup>3</sup> , <i>oaxaca</i> <sup>3</sup> , <i>ocampo</i> <sup>3</sup> , <i>pictus</i> <sup>4</sup> , <i>pie</i> <sup>3</sup> , <i>potosi</i> <sup>3</sup> , <i>soledad</i> <sup>3</sup> , <i>sotano</i> <sup>3</sup> , <i>tequila</i> <sup>3</sup> , <i>xilitla</i> <sup>3</sup> , <i>yolo</i> <sup>3</sup>	Mexico
<i>aemulus</i> <sup>1</sup> , <i>alternatus</i> <sup>2</sup> , <i>karli</i> <sup>8</sup> , <i>terrell</i> <sup>3</sup> , <i>unicolor</i> <sup>11</sup> ( <i>isolatus</i> )	USA, Mexico
<i>gnaphosoides</i> <sup>6</sup> ( <i>petersi</i> )	Mexico to El Salvador
<i>guerrerensis</i> <sup>7</sup>	Mexico and possibly Central America

1=Gertsch, 1935; 2=Gertsch & Davis, 1936; 3=Platnick & Ubick, 2007; 4=Simon, 1895; 5=Simon, 1888; 6=OP-Cambridge, 1892; 7=Gertsch & Davis, 1940; 8=Gertsch & Riechert, 1976; 9=OP-Cambridge, 1896; 10= OP-Cambridge, 1898; 11=Banks, 1901. Sinonimia = ( ).



Map 1: Distribution of some species of *Zorocrates* in Mexico.



Map 2: Municipal location of the case of araneism caused by *Zoroocrates* sp. (red dot).<sup>[9]</sup>

## THE VENOM

There are no known studies in which the venom of any species of this genus has been characterized. The authors of the only clinical case report argue that the injuries produced were due to the mechanical effect of the bite rather than the damage caused by the poison.<sup>[5]</sup>



## DISCUSSION AND CONCLUSIONS

In Mexico, most cases of araneism are due to spider bites of the *Loxosceles* and *Latrodectus* genera, with clinical evolution of different magnitudes including death. Although there are no records on this problem, there are reports of mild to moderate intensity effects by species such as *Kukulcania hibernalis*, *Kukulcania tractans* and *Zorocrates guerrerensis*; in Arizona<sup>[17]</sup>, in Morelos, Mexico<sup>[4]</sup> and Mexico City, respectively.<sup>[7]</sup>

Since this health problem is poorly understood, as are the species that cause them, diagnosis is often difficult, as is the identification of the arachnid involved. Consequently, timely attention to spider bite cases is important, especially when the arthropod in question is not captured and readily identified. The calculation of 2.0% of spiders of medical importance, results from the consideration of the species included in the ICD-11, as long as all species are involved, methodology used by Hauke and Herzig, 2017;<sup>[18]</sup> However, within the same genus, not all species have the same degree of toxicity (eg *Latrodectus*), so the clinical picture will vary in their level of severity.

In conclusion, immediate medical attention should be requested to avoid complications that may leave sequels or lead to death in the case of spiders considered of relevant medical importance. Also, register these events to determine the epidemiology of araneism in our country. Finally, collaborative and multidisciplinary work between physicians and arachnologists is required to deal with serious cases efficiently and effectively. In Mexico there are specific antivenoms for the treatment of poisoning by *Latrodectus* and *Loxosceles* spiders, with extraordinary results when applied in a timely manner.

## REFERENCES

1. D'Suze G, Corzo BGA, Paniagua SJF. Emergencias por animales ponzoñosos en las Américas. México: Instituto Bioclon, S.A. de C.V., 2011.
2. Vetter RS. Spider envenomation in North America. *Critical care nursing clinics of North America*, 2013; 25(2): 205-23.
3. Ramos RHG, Méndez JD. Araña "Violinista" (*Loxosceles* sp). México: Corposec, 2016.
4. Ramos RHG, Valdez MA, Méndez JD. Araneism by *Kukulcania cf tractans* in mature adult male from Mexico: A case report. *WJPR*. 2019; 8(3): 120-129.
5. International Classification of Diseases. <https://icd.who.int/browse11/l-m/en> (November 2019).
6. World Spider Catalog, Version 20.5. <https://wsc.nmbe.ch/> (November 2019).

7. Sánchez-Vega JT, Durán-Barrón CG, Olguín-Pérez L, Cabrera-Fuentes H, Cruz-García JQ. Necrotic Arachnidism by *Zorocrates guerrerensis*. First case reported in Mexico. Clin Dermatol Res J., 2016; 1: 1-4.
8. Aguilera MA, Casanueva ME. Chilean spiders: current state of knowledge and key to the areanomorphae families. Gayana, 2005; 69(2): 201-224.
9. Platnick NI, Ubick D. A revision of the spider genus *Zorocrates* simon (Araneae, Zorocratidae). American Museum Novitates, 2007; 3579: 1-44. DOI: [https://doi.org/10.1206/0003-0082\(2007\)3579\[1: AROTSG\]2.0.CO;2](https://doi.org/10.1206/0003-0082(2007)3579[1: AROTSG]2.0.CO;2)
10. Torres N, Rueda M. Cutaneous loxoscelism: extensive non-ulcerated livedoid plaque. Braz J Infect Dis., 2017; 21(3): 353-354.
11. Dolejs P, Hanko M. Ontogenetic development and reproduction of *Zorocrates guerrerensis* (Araneae: Zoropsidae) Arachnologische Mitteilungen: Arachnology Letters., 2018; 55(1): 46-51.
12. García-Balderas CM, Quintero Díaz GE, Lucio-Palacio CR, Valdéz-Jiménez D. 2014; CONOPSIS LINEATA (Lined Toluca Ground Snake). DIET. Herpetological Review 45(2): 337.
13. Desales-Lara MA, Francke FO, Sánchez-Nava P. Diversidad de arañas (Arachnida: Araneae) en hábitats antropogénicos. Revista Mexicana de Biodiversidad. 2013; 84: 291–305.
14. Durán-Barrón CG, Francke FO, Pérez-Ortiz TM. Diversidad de arañas (Arachnida: Araneae) asociadas a viviendas de la ciudad de México (Zona metropolitana). Revista Mexicana de Biodiversidad. 2009; 80: 55–69.
15. Fernández RF. La etimología de los nombres de las arañas (Araneae). Revista Ibérica de Aracnología. 2013; 22: 125-130.
16. Species list for *Zorocrates*. <http://www.wsc.nmbe.ch/specieslist/3908> (November 2019).
17. Skolnik AB, O'Connor A, Olson CA, Heise CW. Dermatonecrosis following *Kukulcania hibernalis* (southern house spider) bite. 2013 Annual meeting of the north american congress of clinical toxicology (NACCT). Clin Toxicol., 2013; 51: 575-724.
18. Hauke TJ, Herzig V. Dangerous arachnids-fake news or reality?. Toxicon., 2017; 138: 173-183.